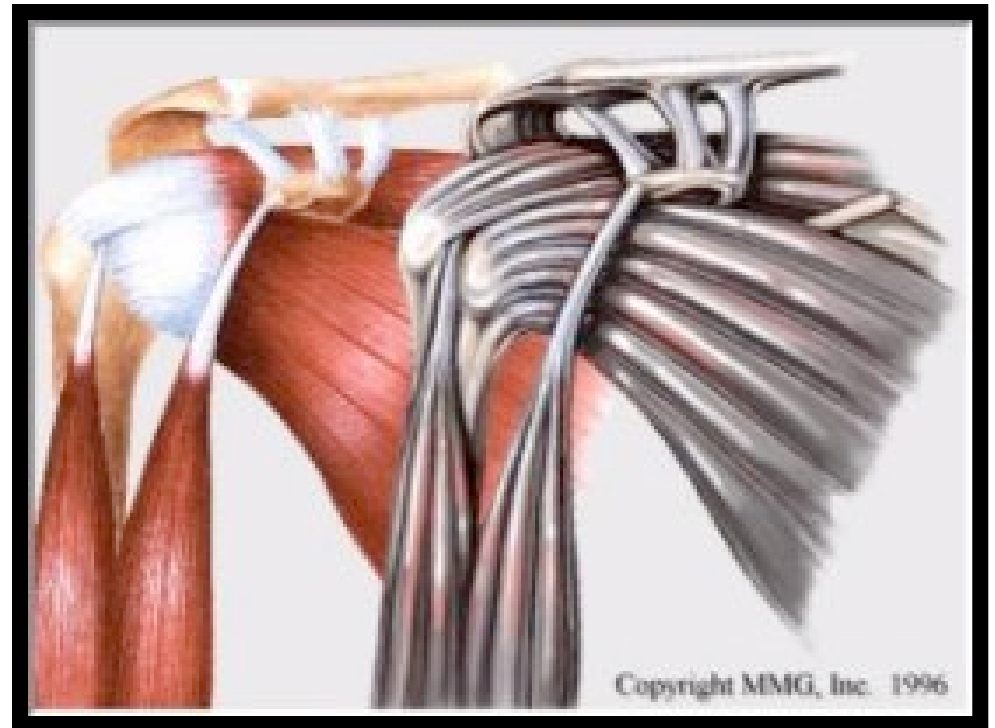


Shoulder Muscles

Chapter 5

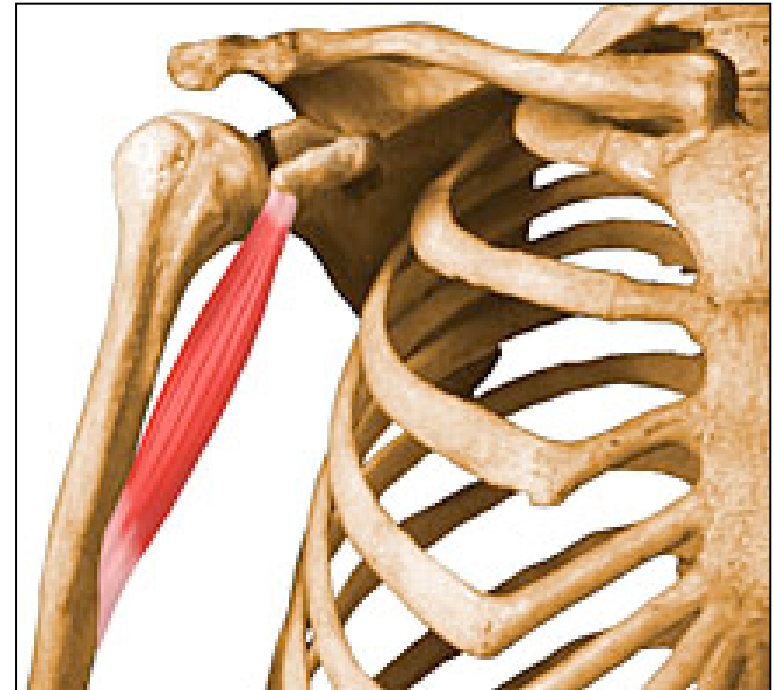
Anterior Muscles

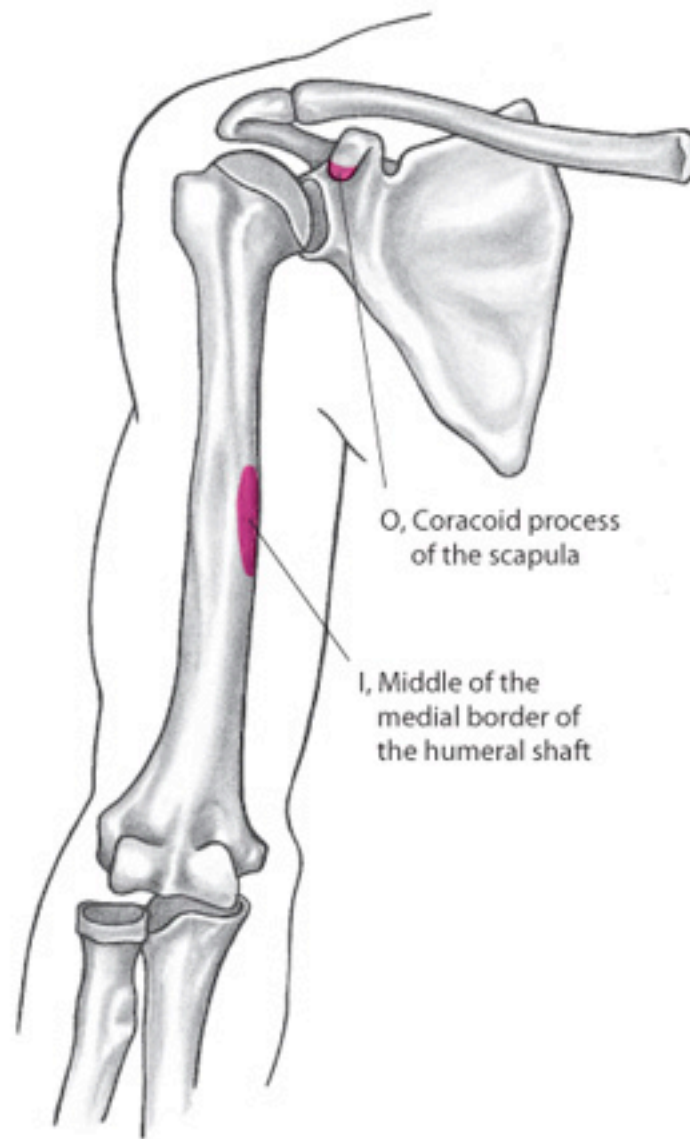
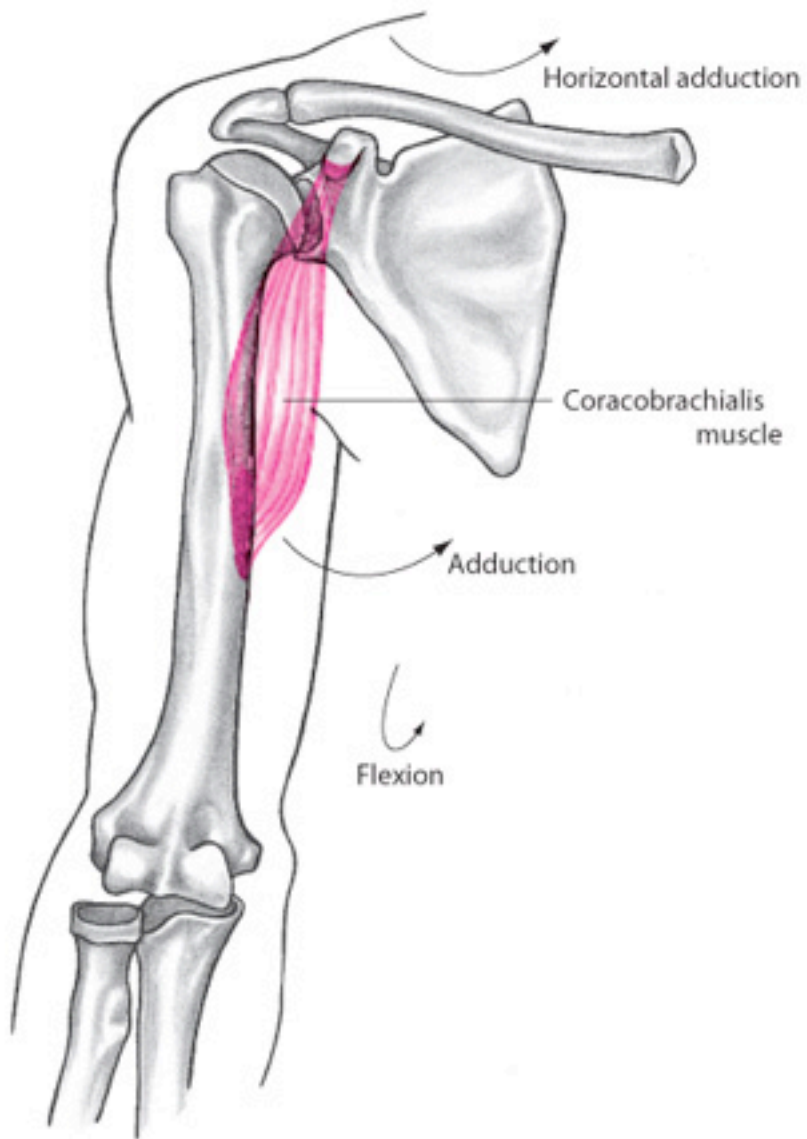
- Coracobrachialis
- Pectoralis major
- Subscapularis



Coracobrachialis

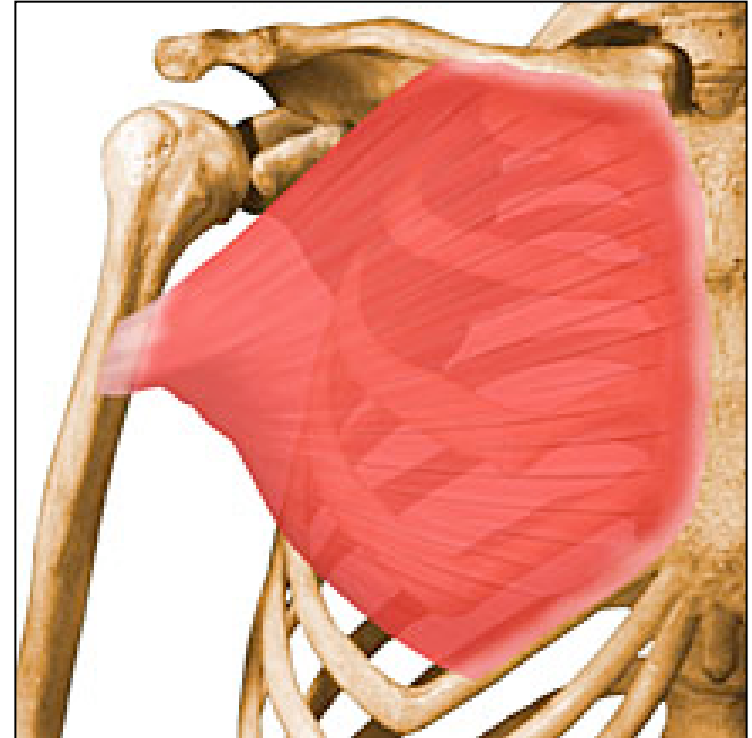
- Origin: coracoid process
- Insertion: medial humerus
- Actions:
 - flexion of the shoulder
 - adduction of the shoulder
 - horizontal adduction of the shoulder





Pectoralis Major

- Origin:
 - Proximal clavical
 - Sternum
- Insertion: Intertubercular groove
- Actions:
 - Clavicular:
 - Internal rotation
 - Horizontal adduction
 - Flexion up to 60°
 - Adduction below 90°
 - Abduction above 90°
 - Sternal
 - Internal rotation
 - Horizontal adduction
 - Extension to a neutral position
 - Adduction



- Pectoralis Major

PECTORALIS MAJOR

Description:

large, thick, fan-shaped muscle covering the superior part of the thorax.

Two parts:

- clavicular head
- sternocostal head

Origin:

- anterior surface of the medial half of clavicle
- anterior surface of sternum and costal cartilages of the upper seven ribs

Insertion:

- intertubercular groove of the humerus

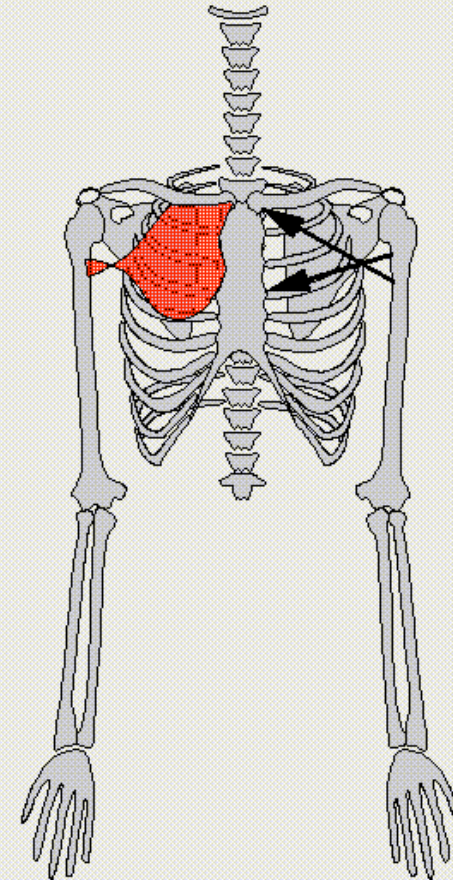
Function:

- flexion of the humerus (clavicular head)
- adduction and medial rotation of the humerus (sternocostal head)

Modelization:

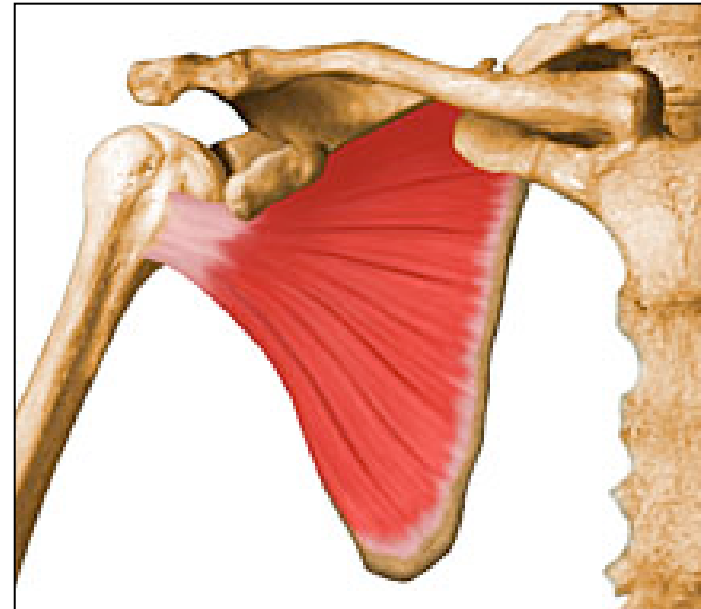
two vectors from clavicle and sternum to intertubercular groove of humerus

Notes:

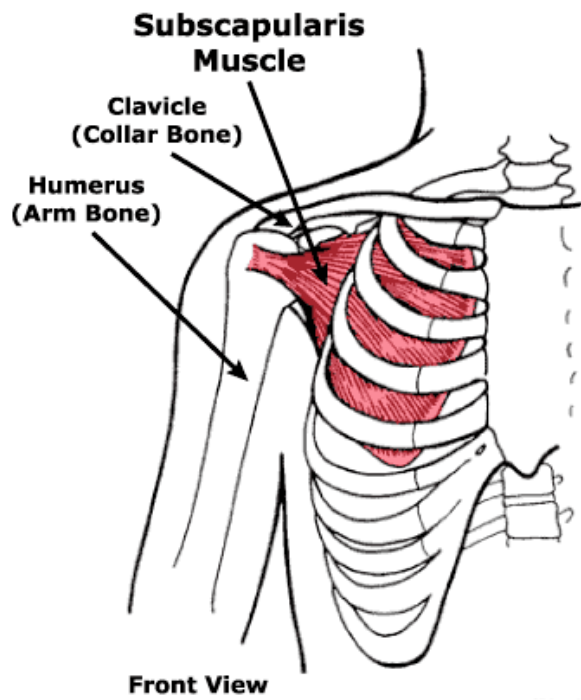


Subscapularis

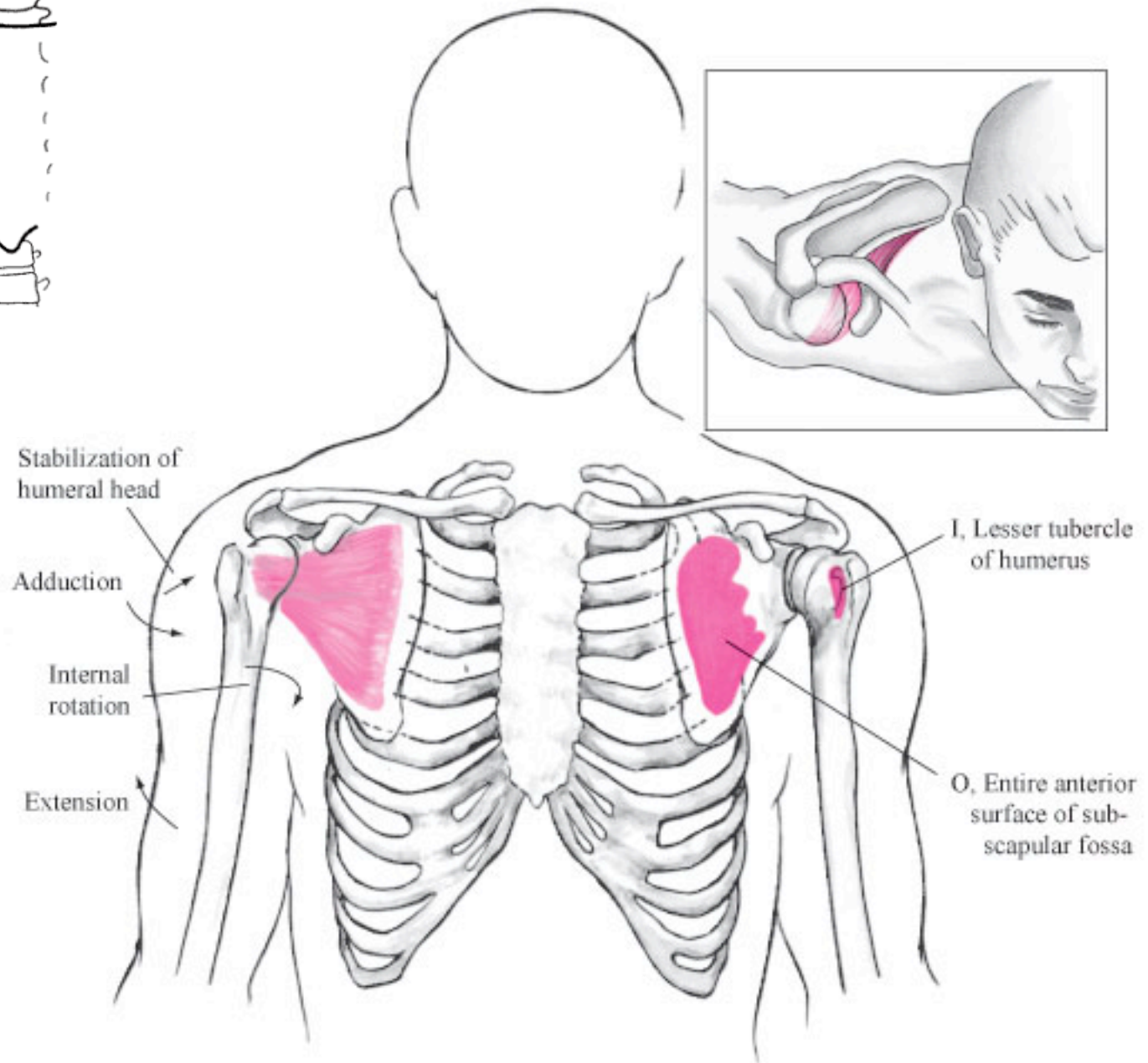
- Origin: subscapular fossa
- Insertion: lesser tubercle
- Actions:
 - Internal rotation
 - Adduction
 - Extension
- Other: anterior rotator cuff muscle



Note: the ribs are removed from this image



Front View

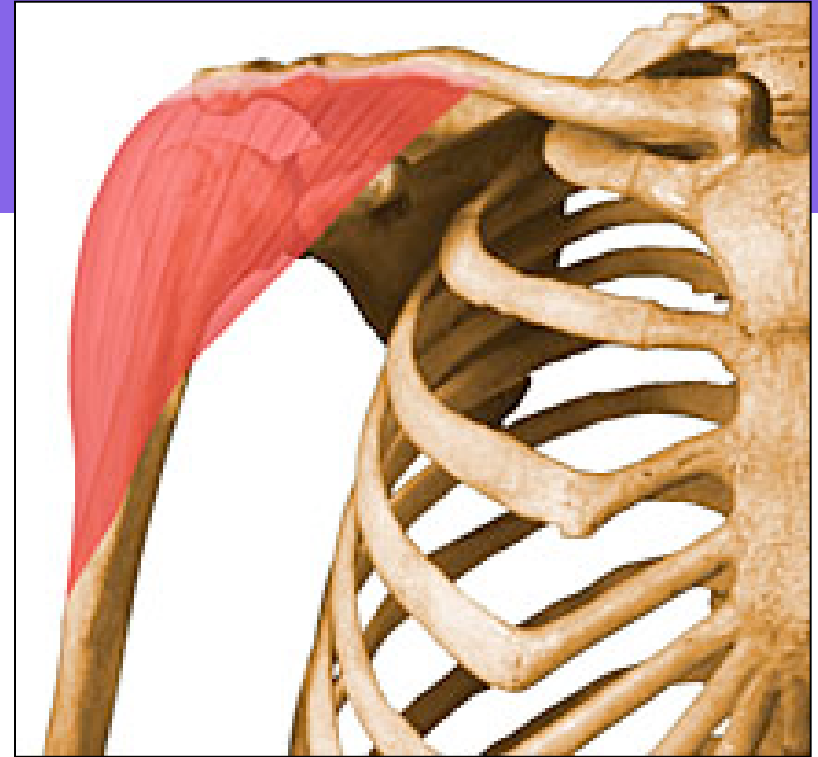

Superior Muscles

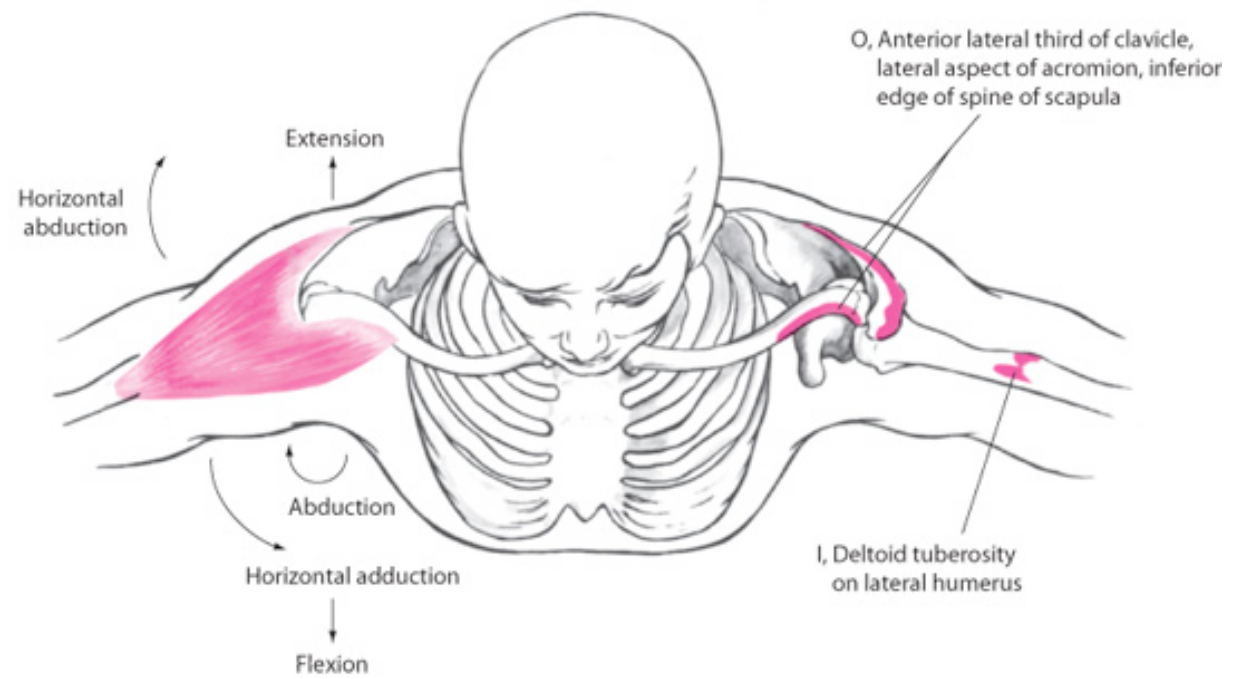
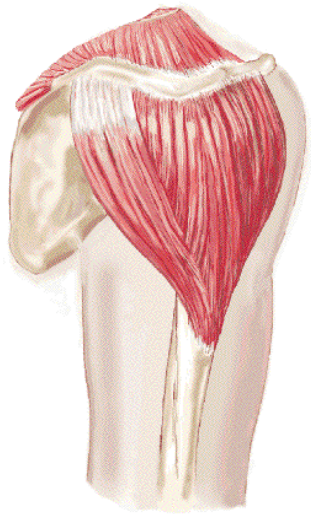
- Deltoid
- Supraspinatus

Deltoid

- Origin:
 - Anterior: distal clavicle
 - Middle: acromion process
 - Posterior: spine of scapula
- Insertion:
- Actions
 - Anterior: flexion, abduction, internal rotation, horizontal adduction
 - Middle: abduction
 - Posterior: extension, abduction, external rotation, horizontal abduction

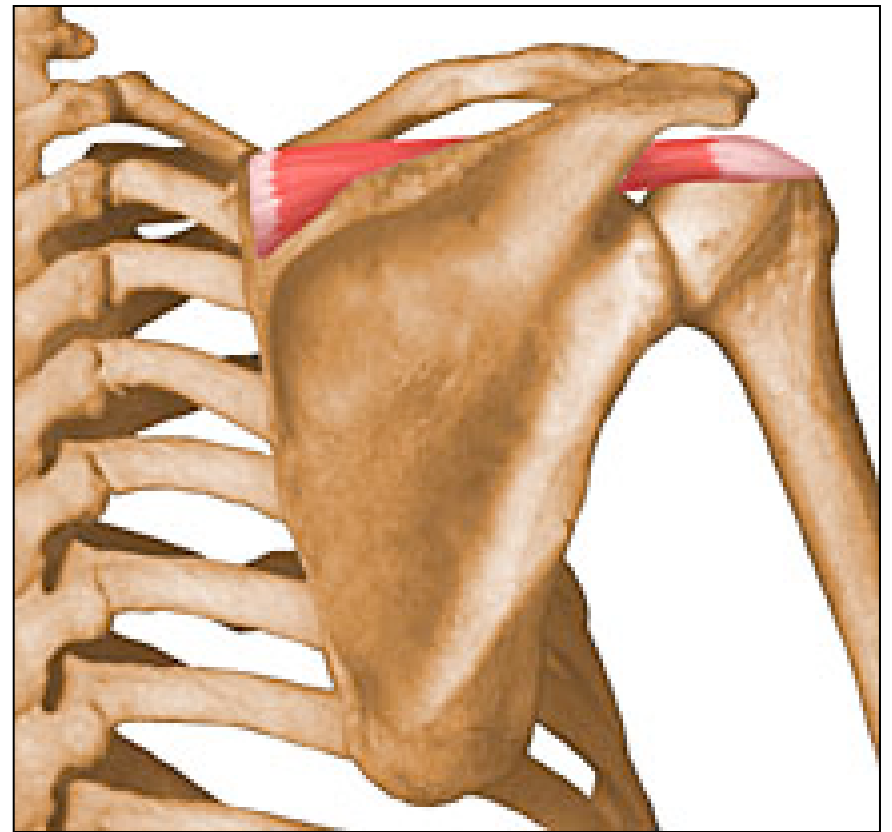


- Deltoid

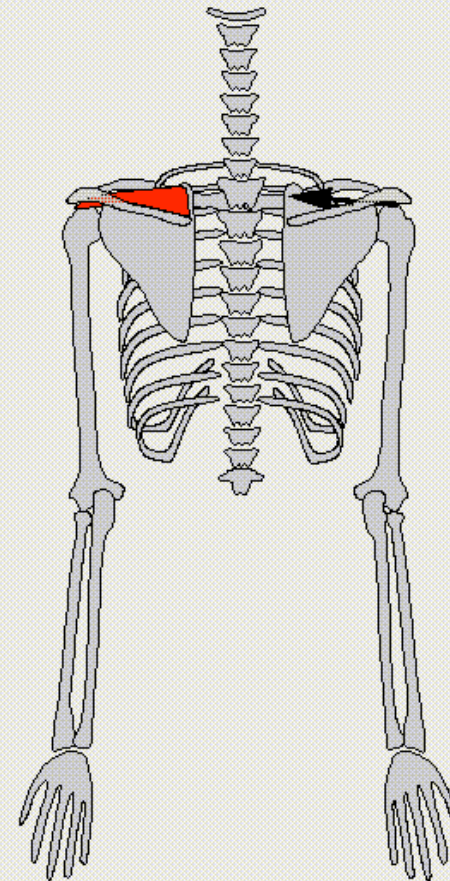
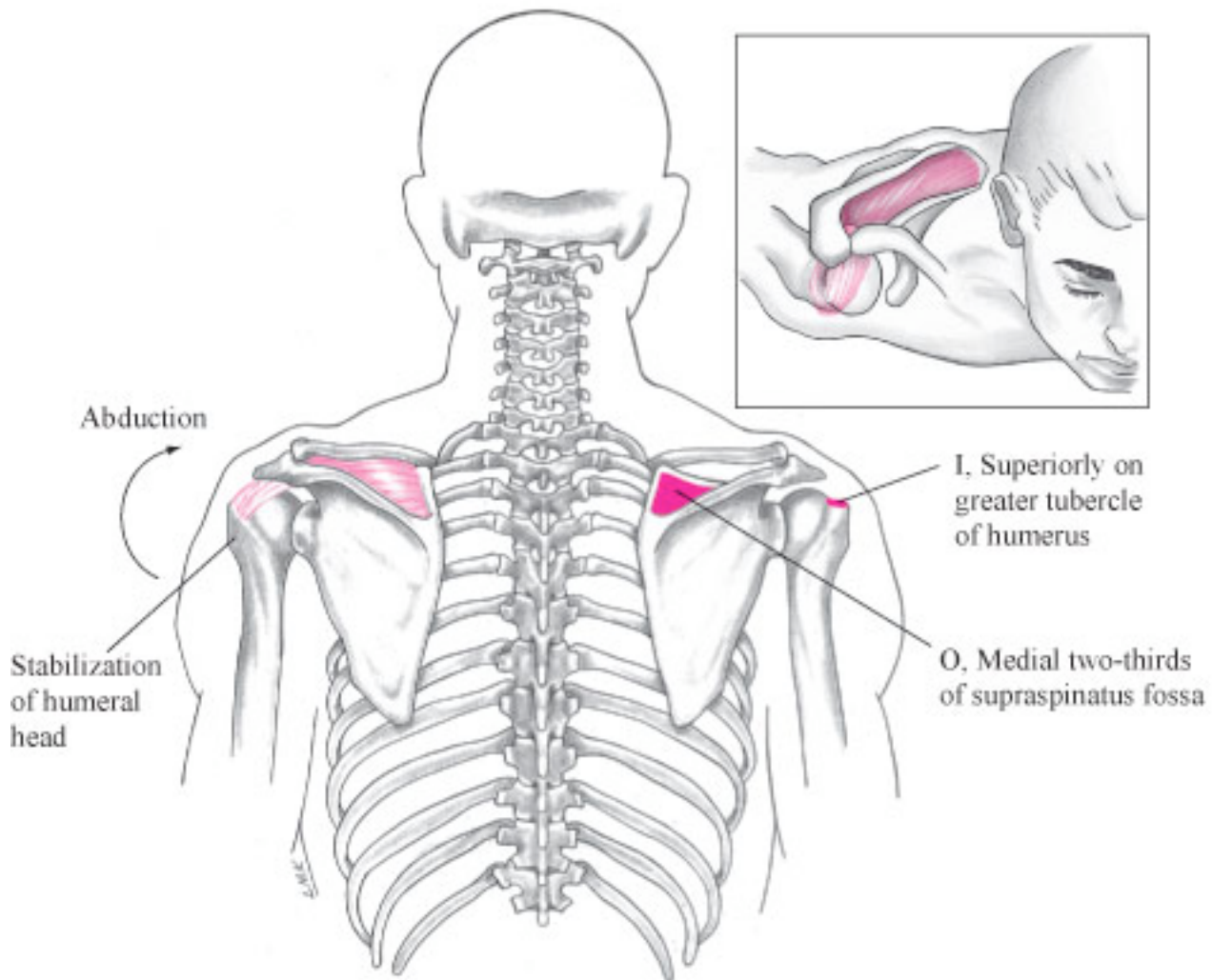


Supraspinatus

- Origin: supraspinatus fossa
- Insertion: greater tubercle
- Action: abduction
- Other: rotator cuff muscle



SUPRASPINATUS

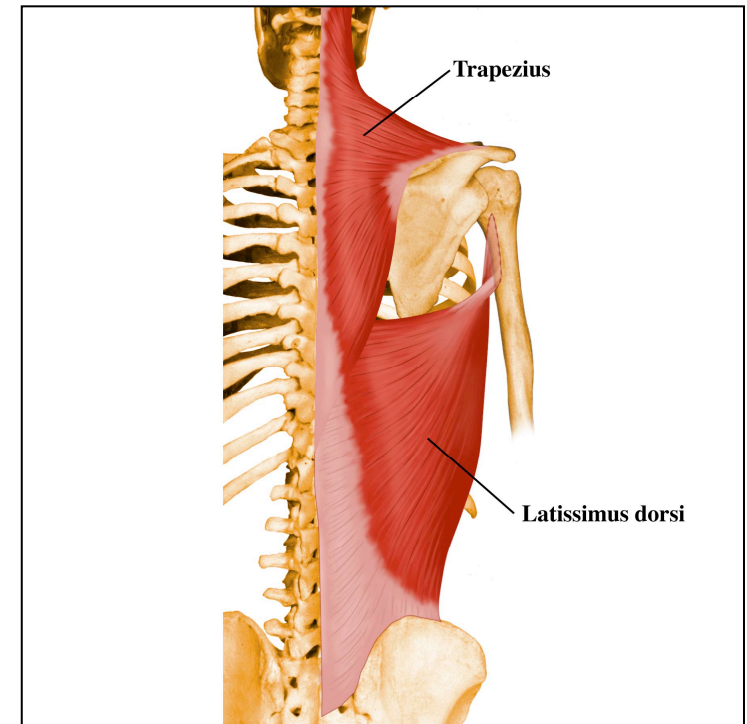


Inferior Muscles

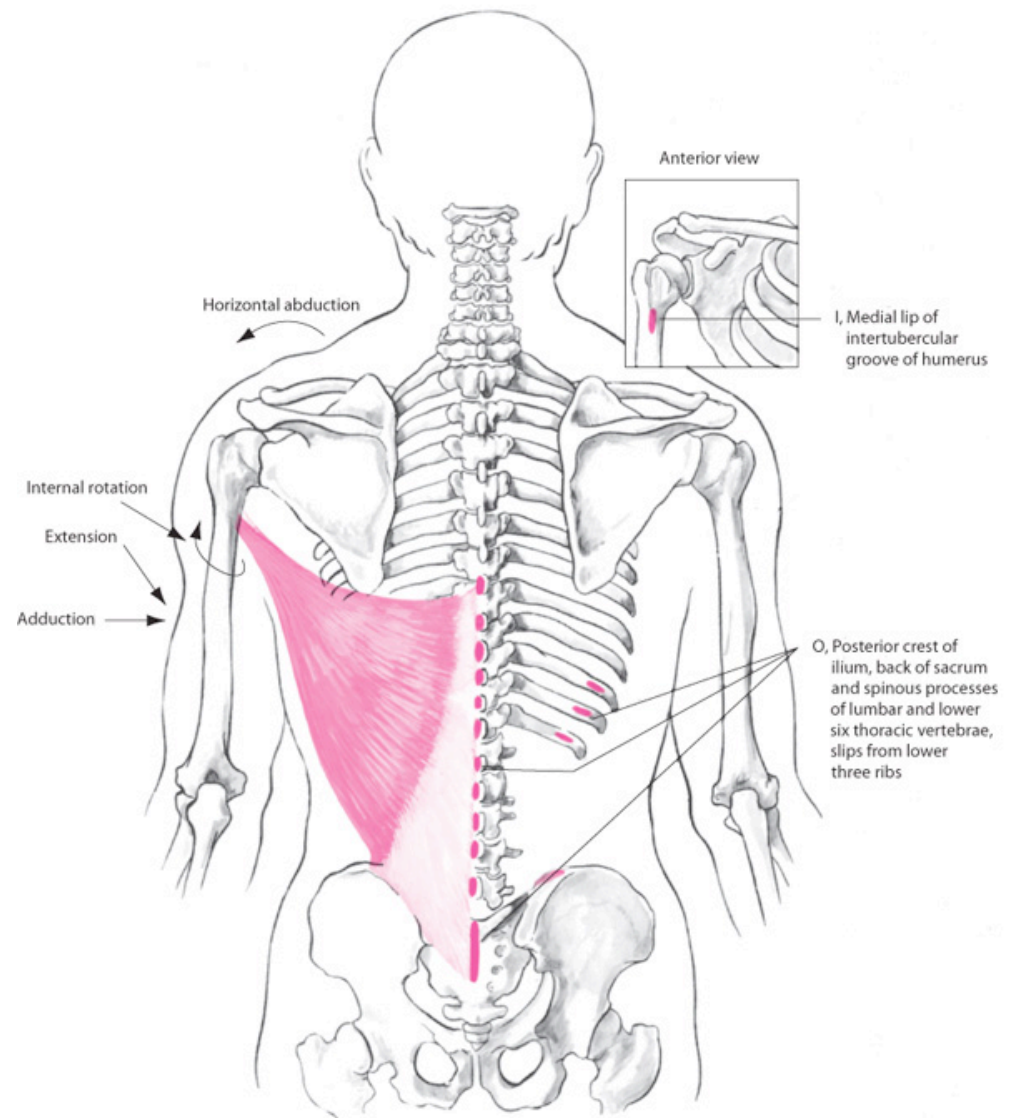
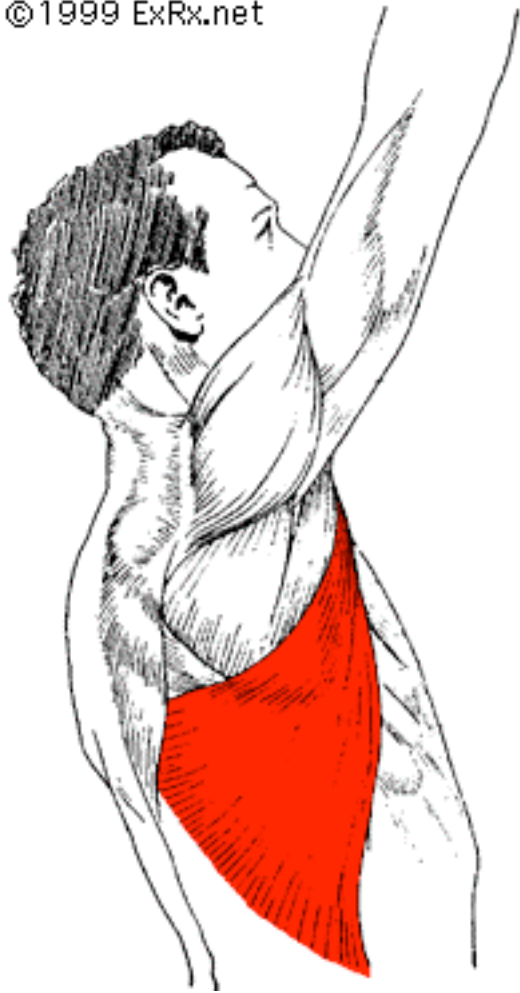
- Latissimus dorsi
- Teres major

Latissimus Dorsi

- Origin:
- Insertion: intertubercular groove
- Actions:
 - adduction
 - internal rotation
 - extension
 - horizontal abduction
- “swimmer’s muscle”

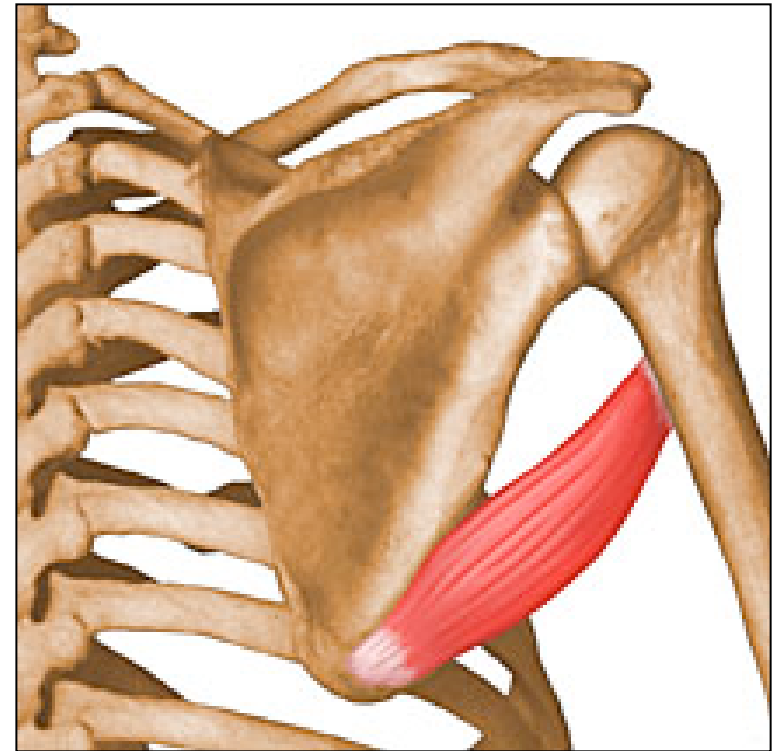


©1999 ExRx.net

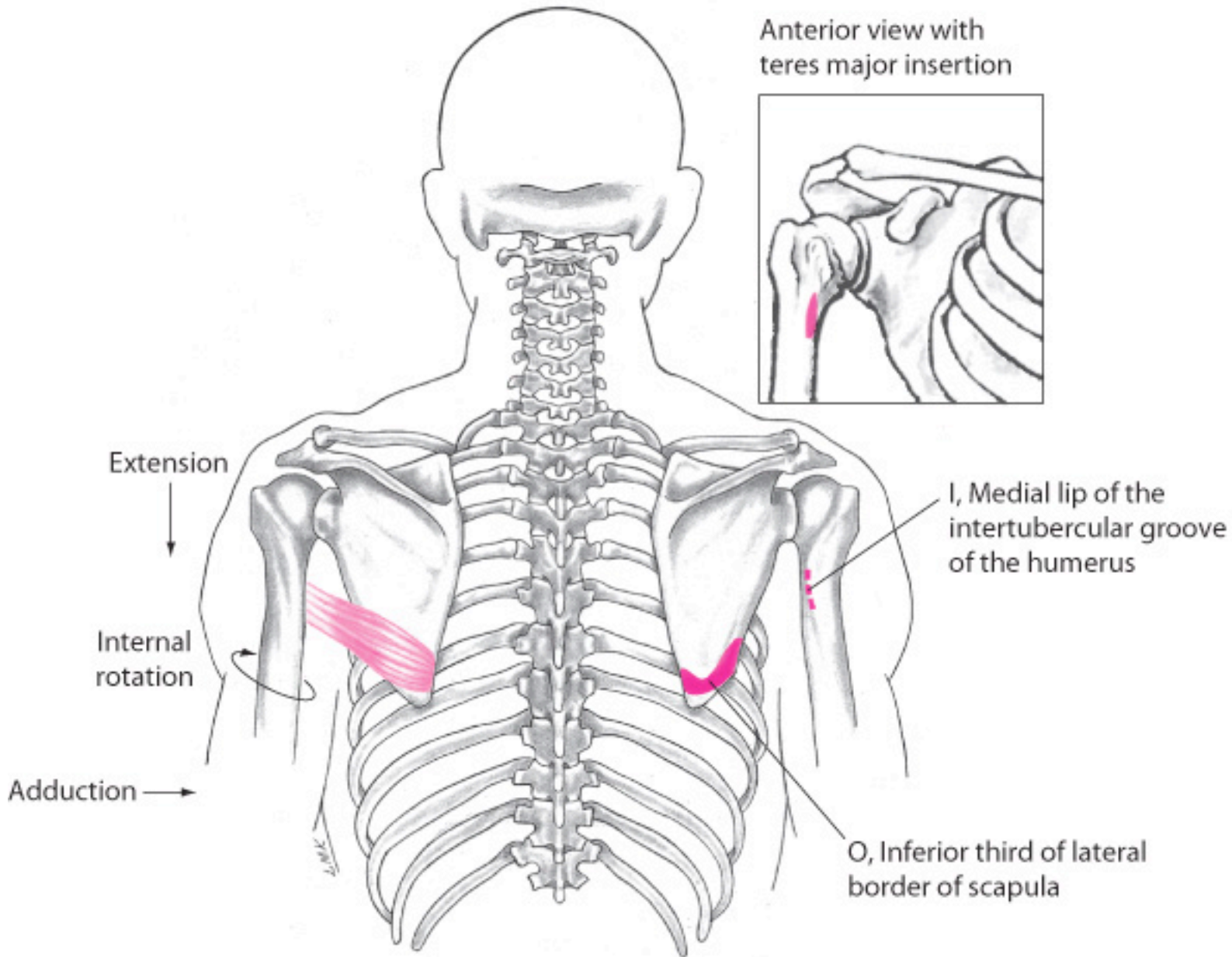


Teres Major

- Origin: inferior angle
- Insertion: intertubercular groove
- Actions:
 - adduction
 - internal rotation
 - extension



“lats little helper”

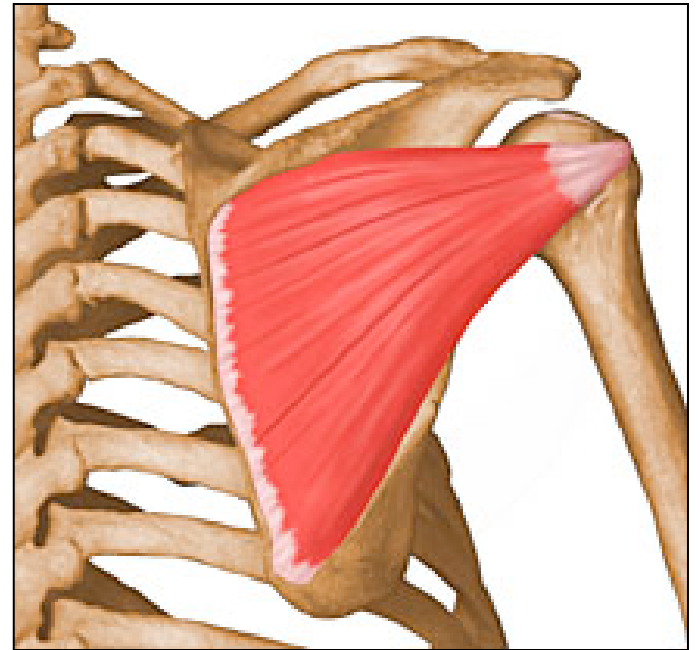


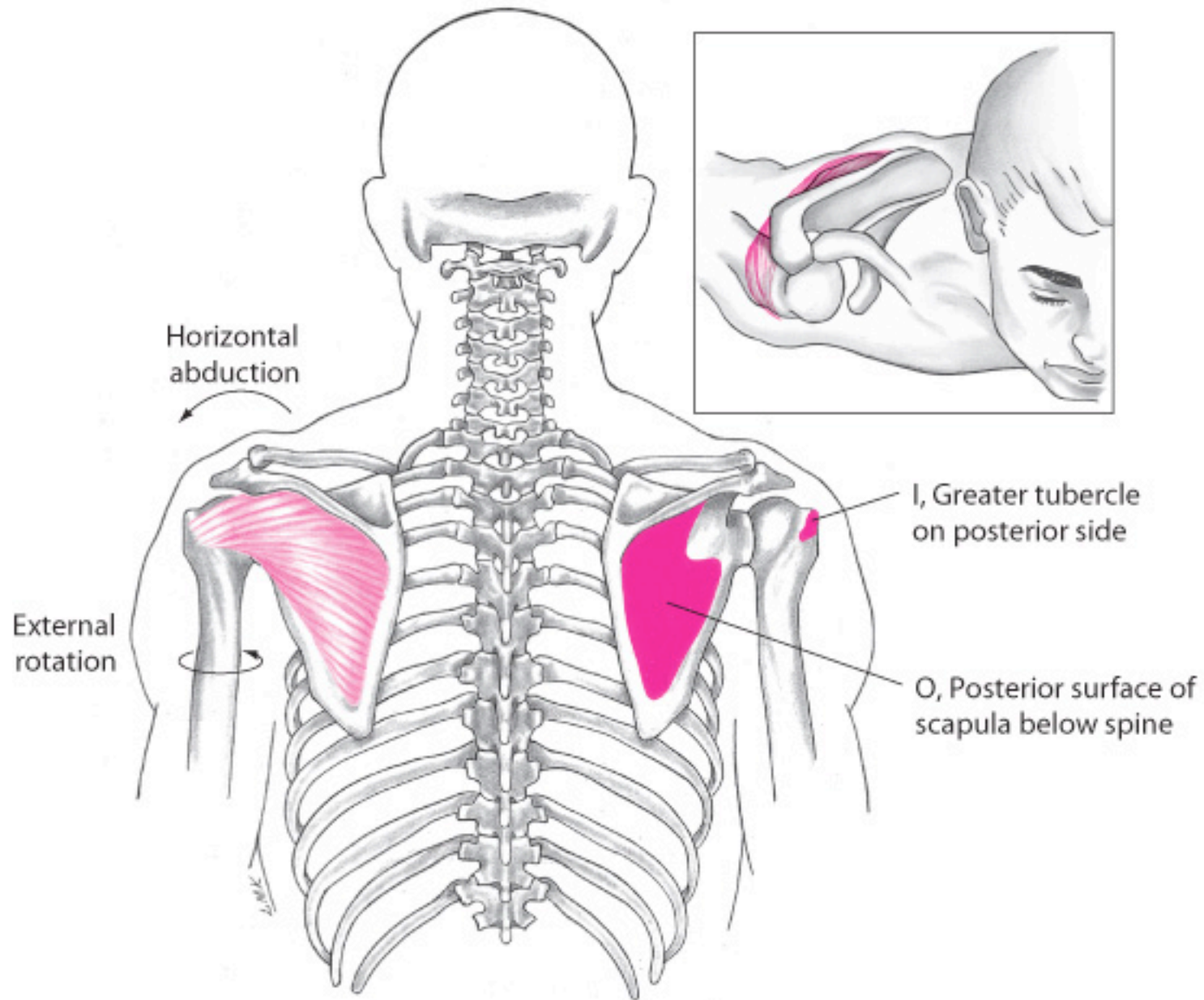
Posterior Muscles

- Infraspinatus
- Teres minor

Infraspinatus

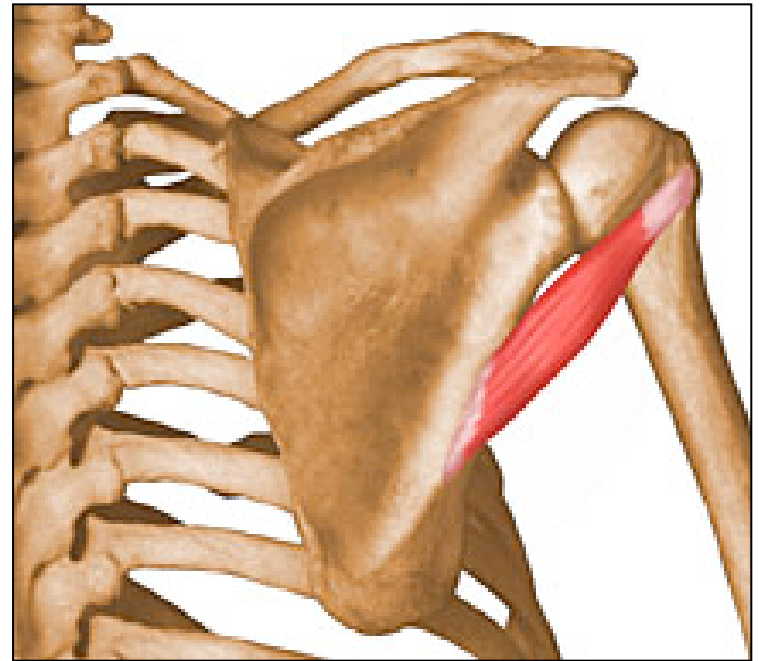
- Origin: infraspinus fossa
- Insertion: greater tubercle
- Actions:
 - extension
 - external rotation
 - horizontal abduction
- Other: rotator cuff muscle

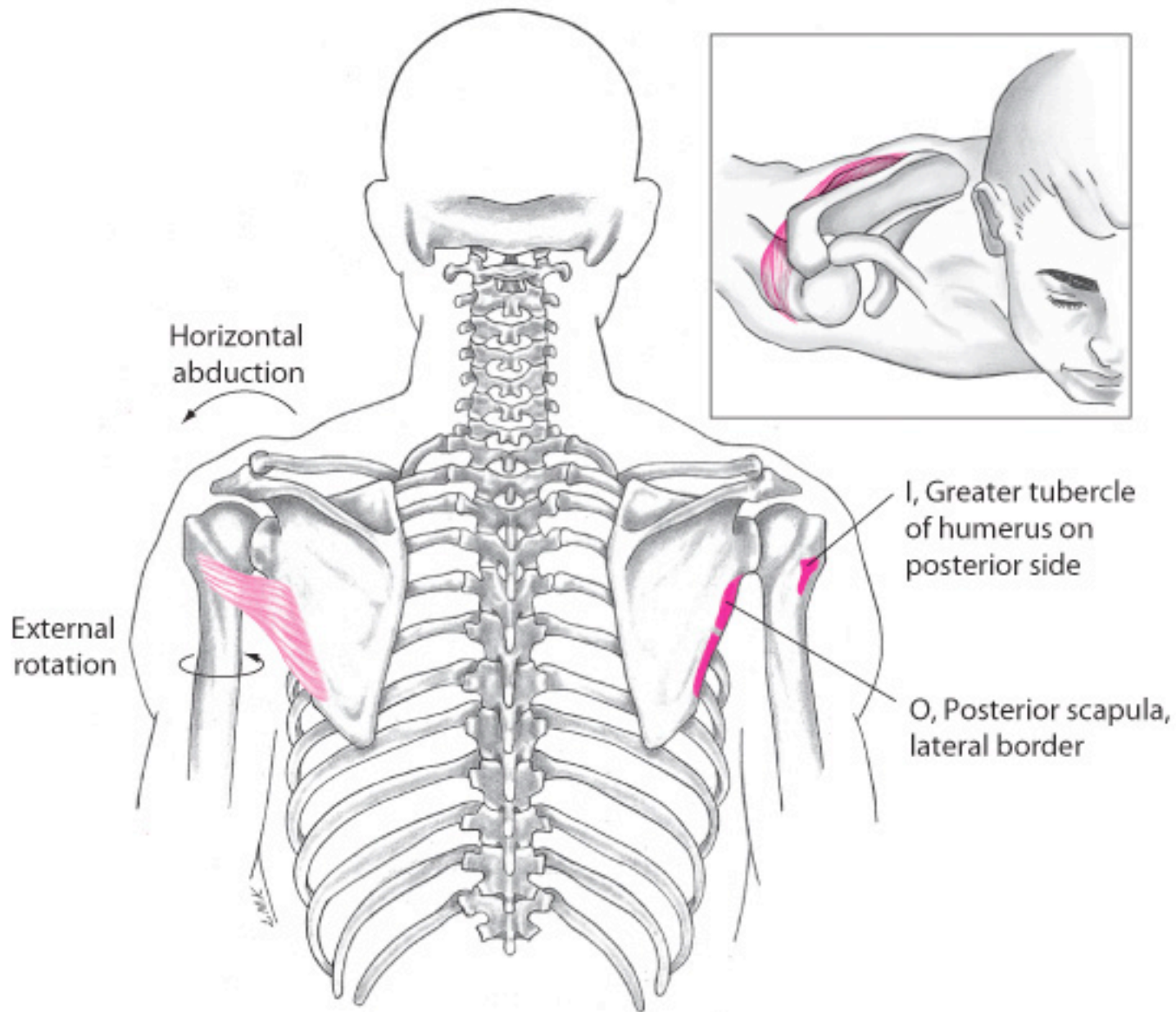




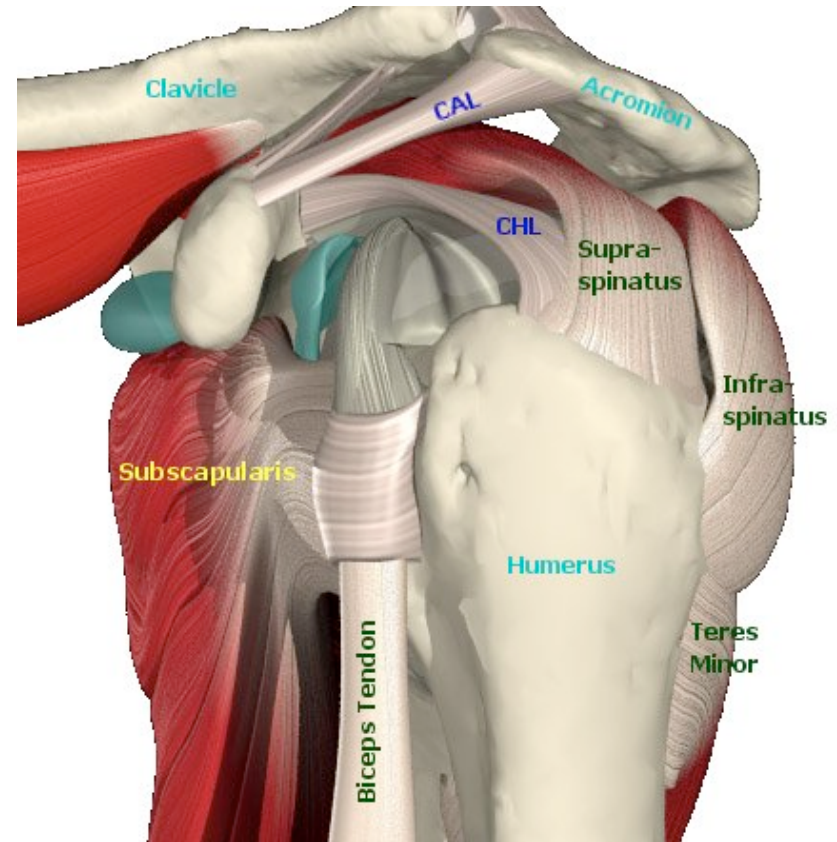
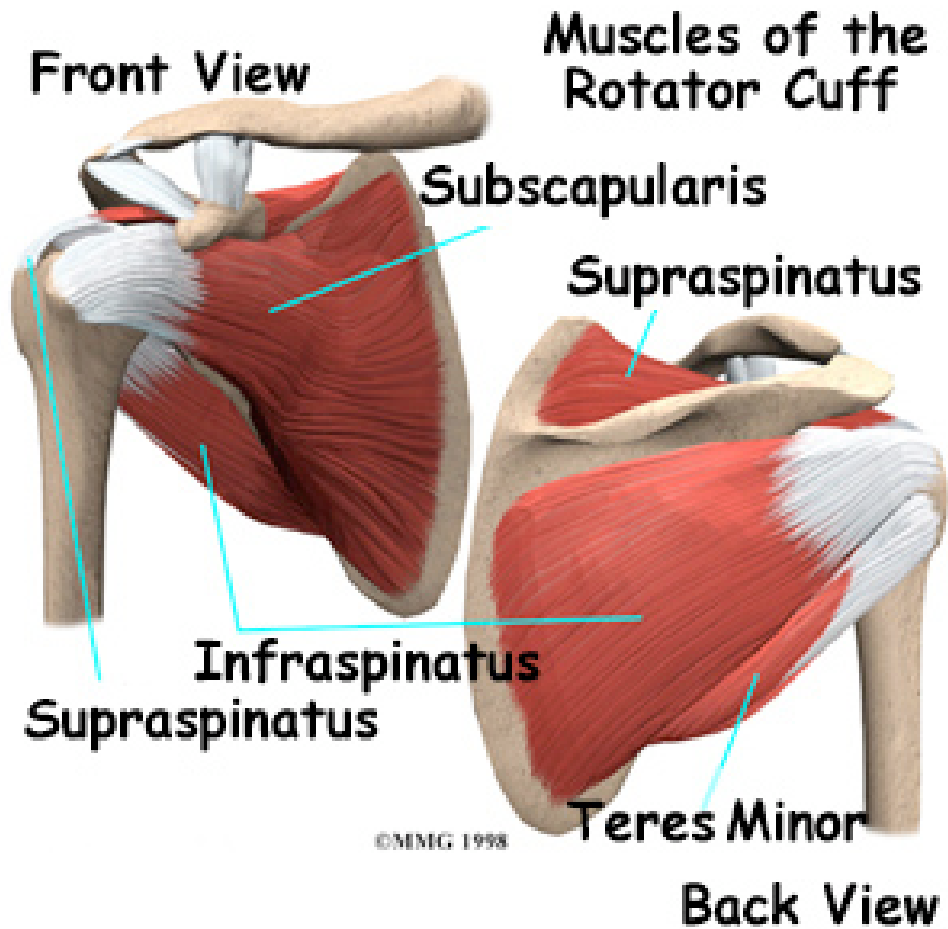
Teres Minor

- Origin: lateral border
- Insertion: greater tubercle
- Actions:
 - extension
 - external rotation
 - horizontal abduction
- Other: rotator cuff

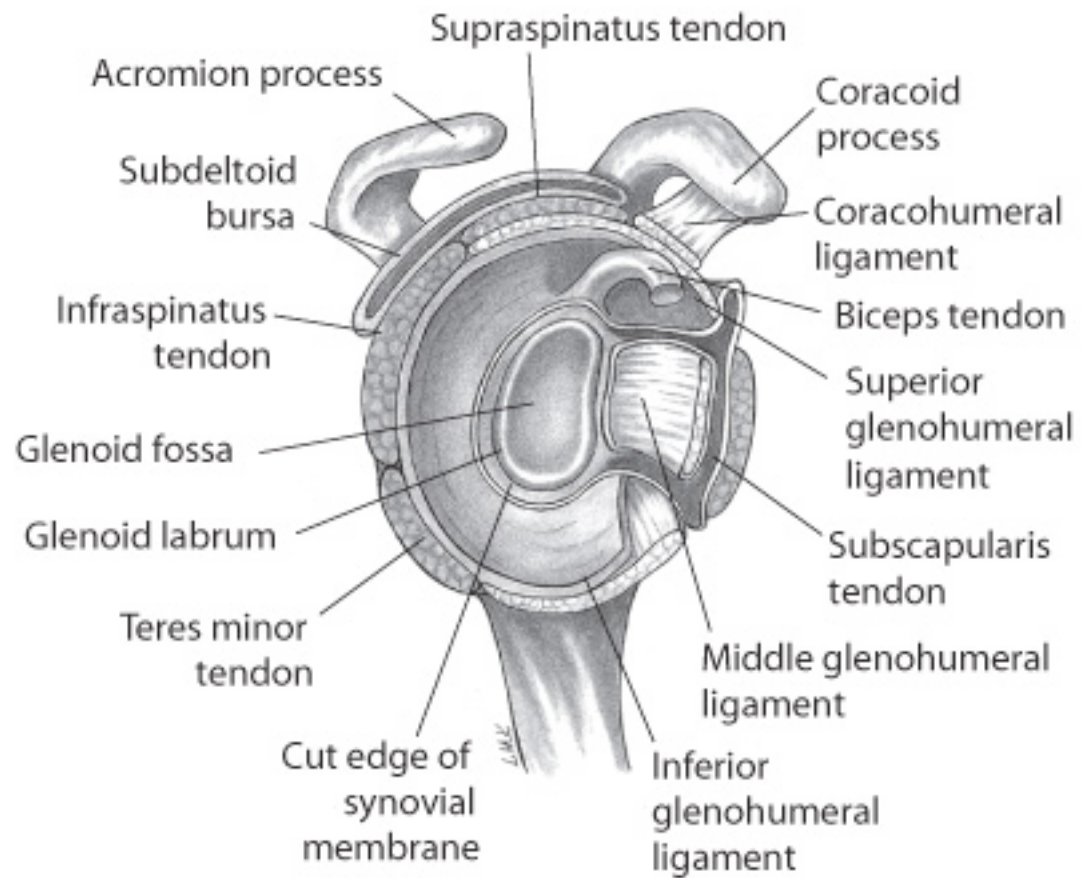
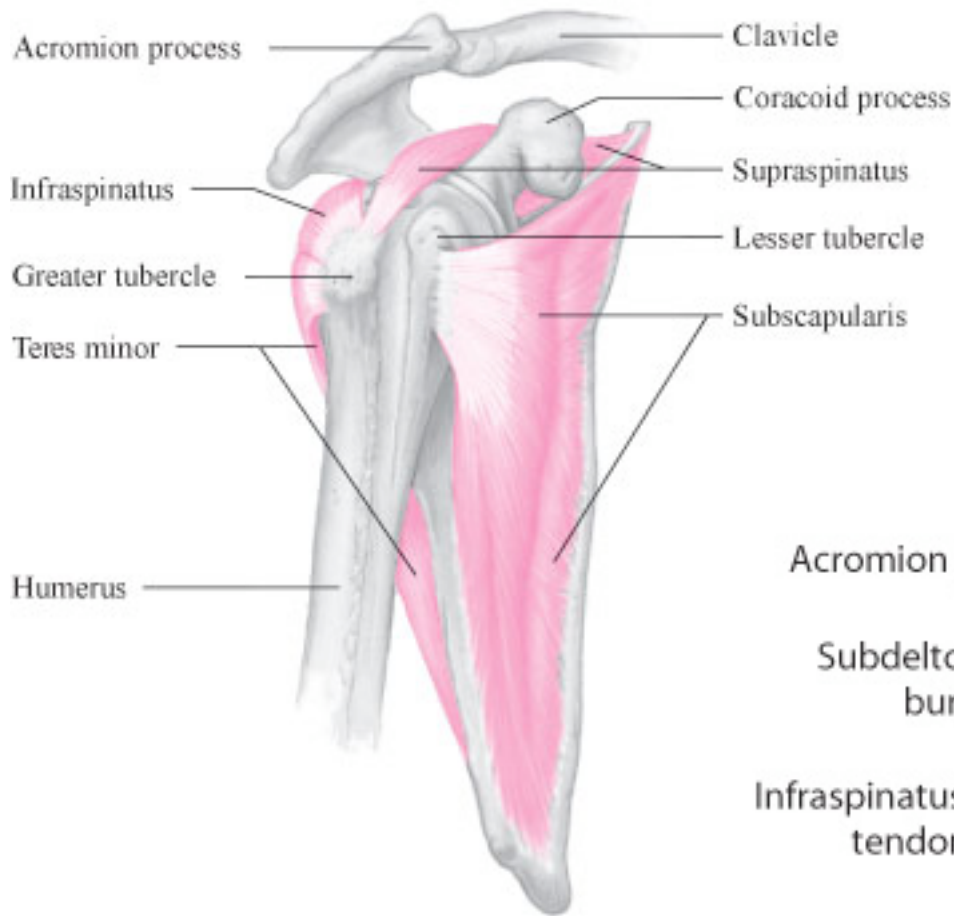




Rotator Cuff Muscles



S.I.T.S



- List the horizontal adduction muscles
 - pectoralis major (upper and lower fibers)
 - corachobrachialis
 - ant. deltoid

- List the horizontal abduction muscles
 - post. deltoid
 - infraspinatus
 - teres minor
 - lat. dorsi

- List the flexor muscles
 - coracobrachialis
 - pect major (upper fibers)
 - ant. deltoid

- List the extensor muscles
 - lat dorsi
 - teres major
 - post. deltoid
 - pect. major (lower fibers)

- List the adductor muscles
 - pect major (upper and lower fibers)
 - coracobrachialis
 - lat. dorsi
 - teres major

- List the abductor muscles
 - deltoid (all fibers)
 - supraspinatus

- List the internal rotator muscles
 - subscapularis
 - lat dorsi
 - teres major
 - ant. deltoid

the end