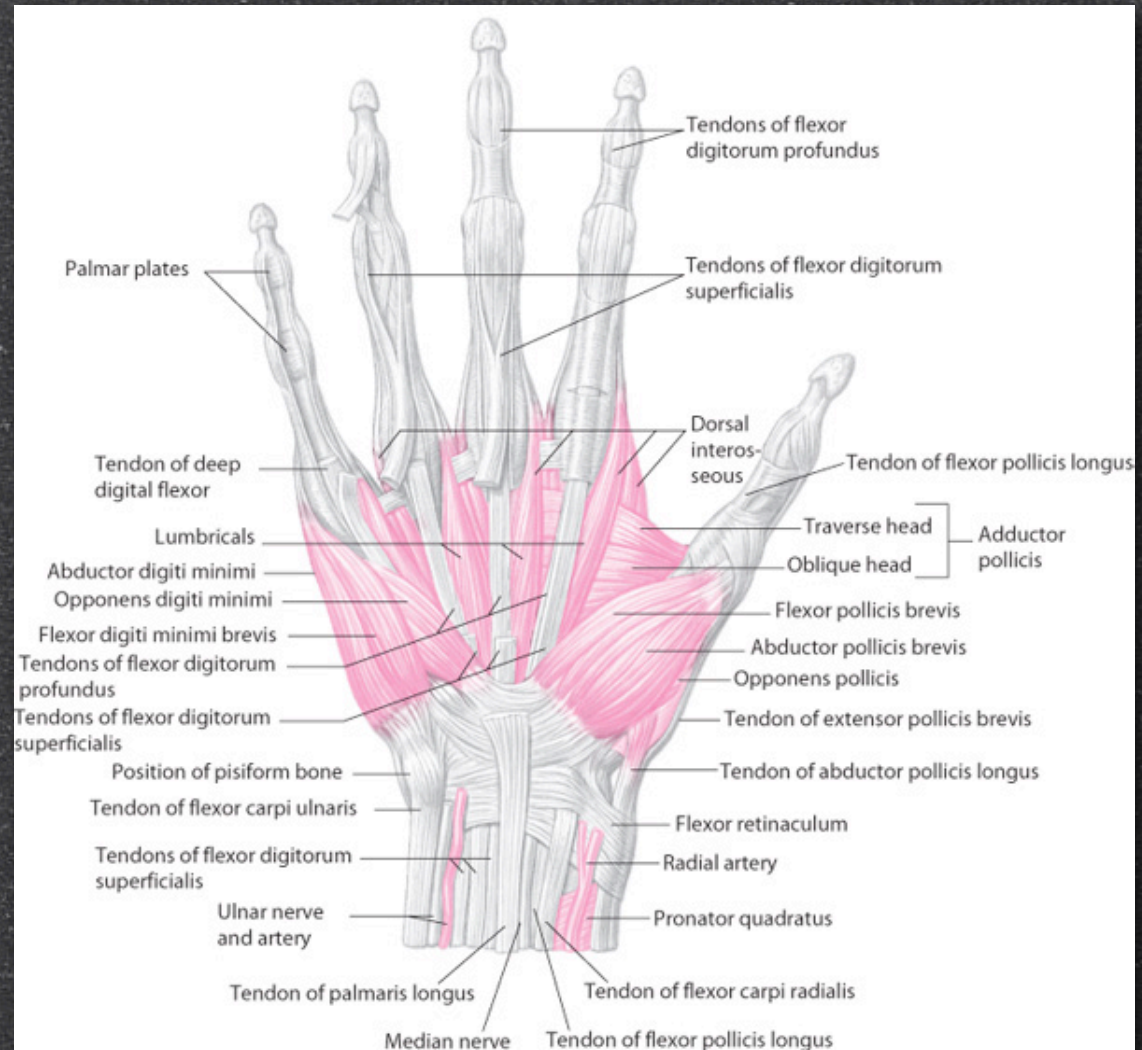


The Wrist and Hand Joints

Applied Information

Intrinsic Muscles

- Thenar eminence
- Hypothenar eminence

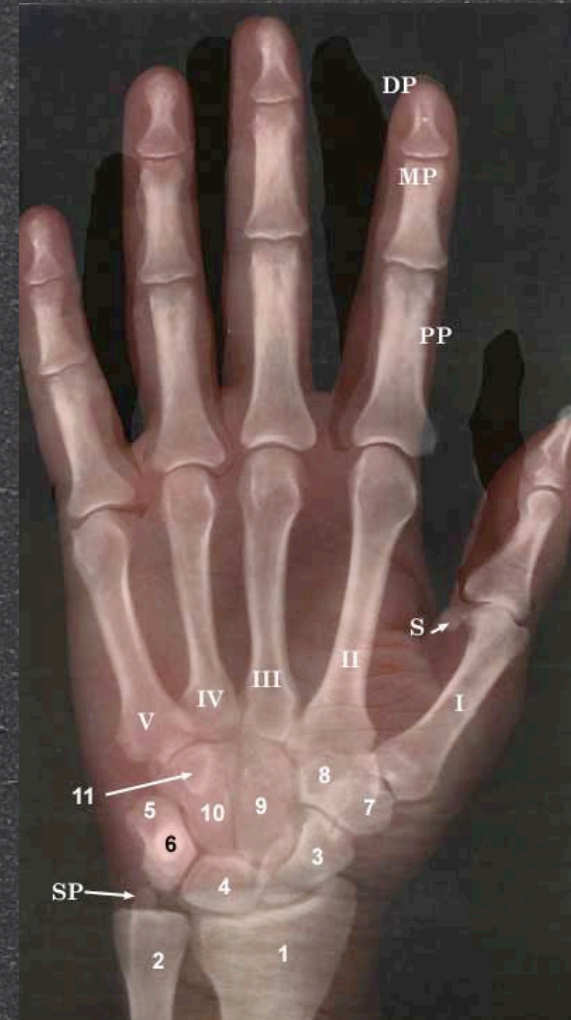

Other Actions

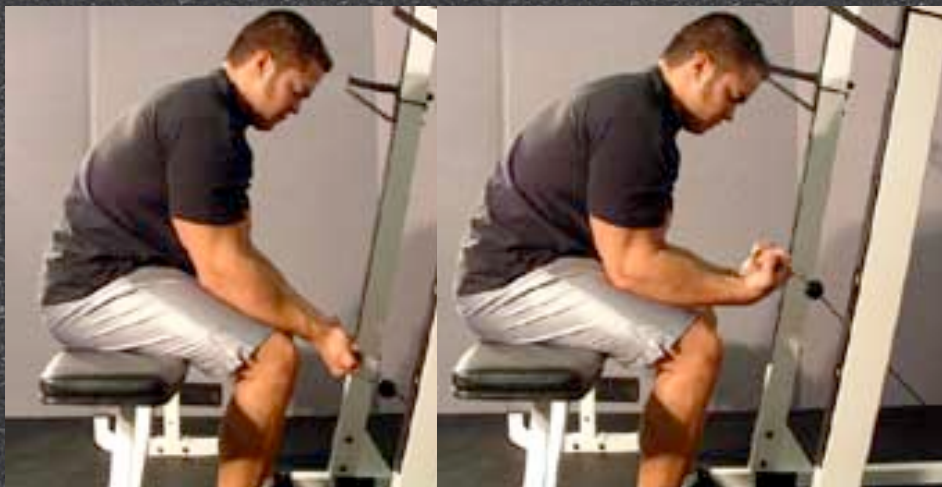- Opposition
- Reposition

Sesamoid Bone





- A small bone imbedded in a tendon.
- Provide a mechanical advantage
 - Knee
 - Flexor tendons of thumb and great toe



Exercises



Exercises

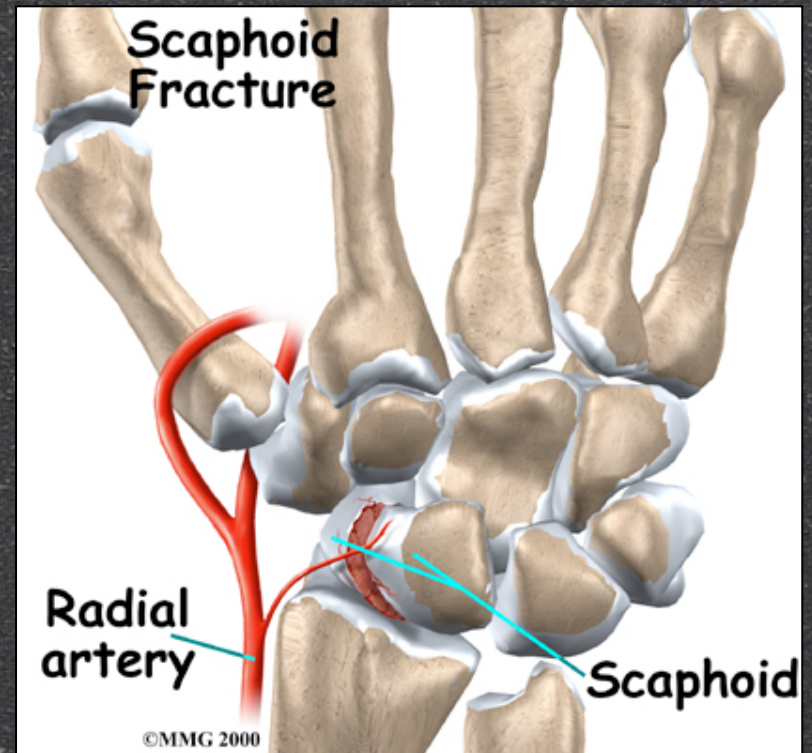
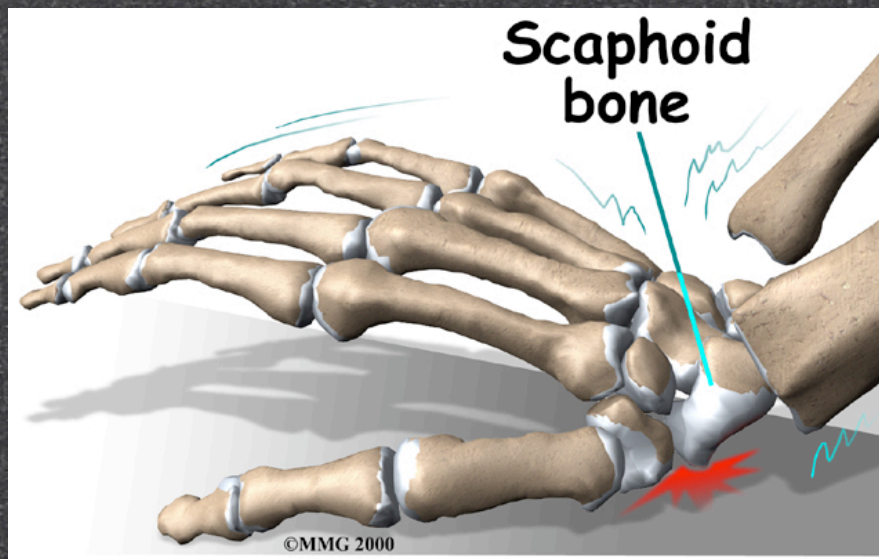


Exercises

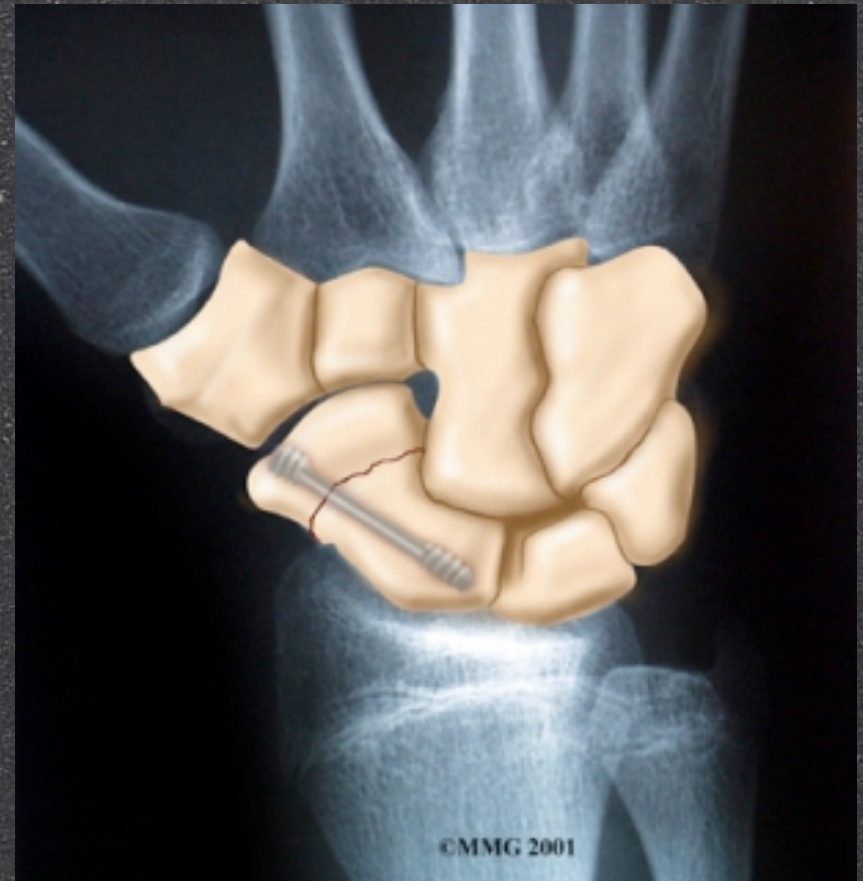
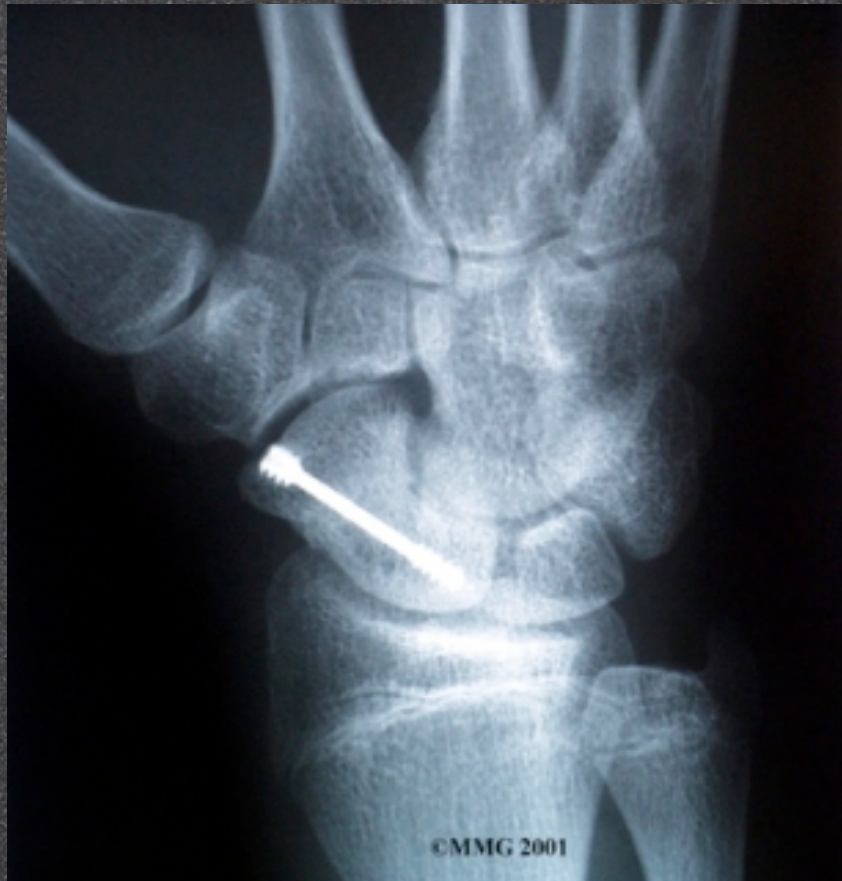
Injuries

Scaphoid Fracture



Scaphoid Fracture



Carpal Tunnel

- The “tunnel”
 - Carpal bones
 - Flexor retinaculum (transverse ligament)
- Flexor tendons and median nerve
- Repetition and overuse
- Swelling and inflammation

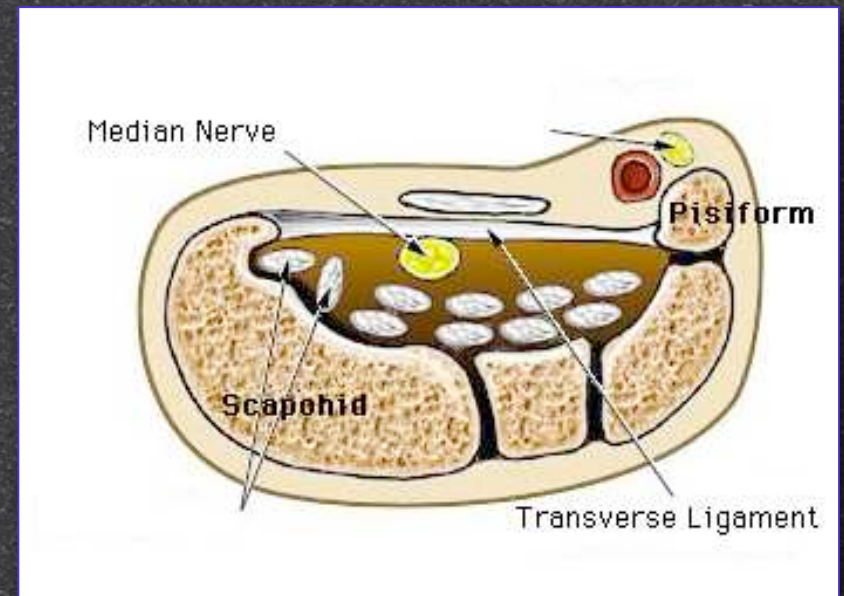


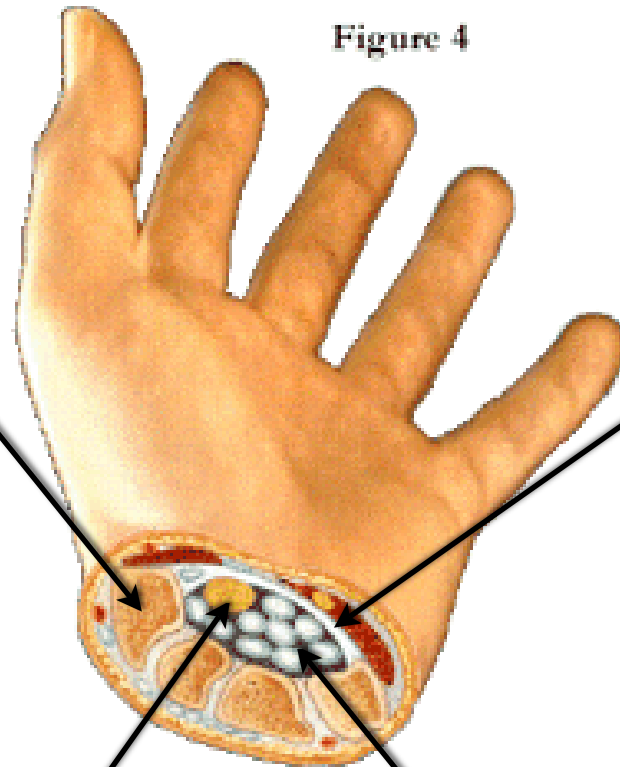
Figure 4

1. Carpal Bones

2. Flexor
retinaculum

3. Median Nerve

4. Flexor Tendons
[except for Flex. Carpi U.
and Palmaris L.]



Median Nerve

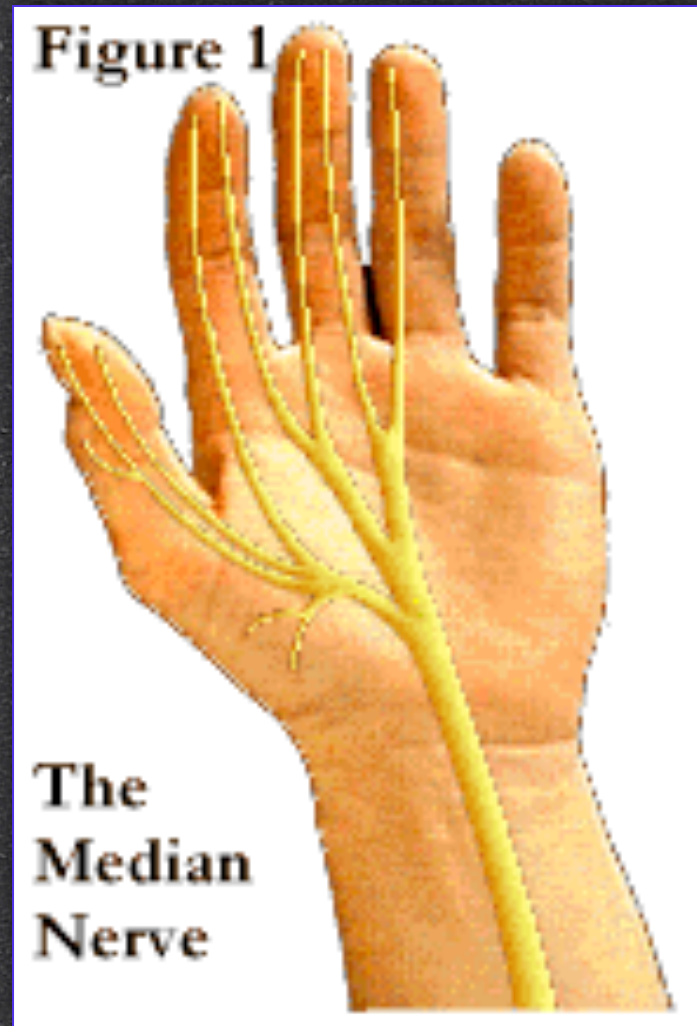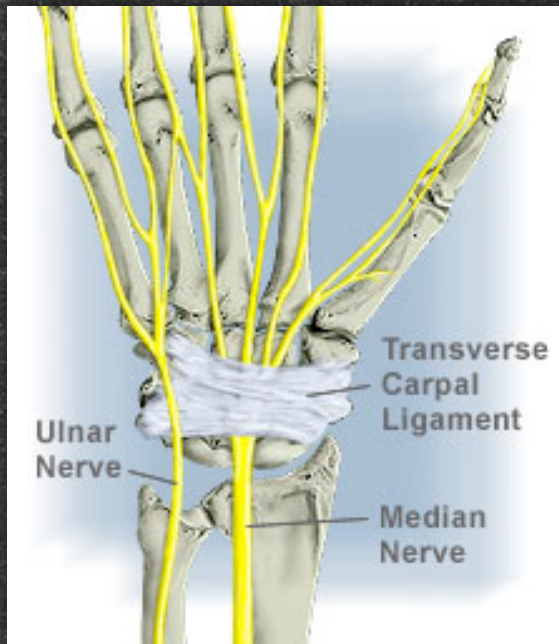
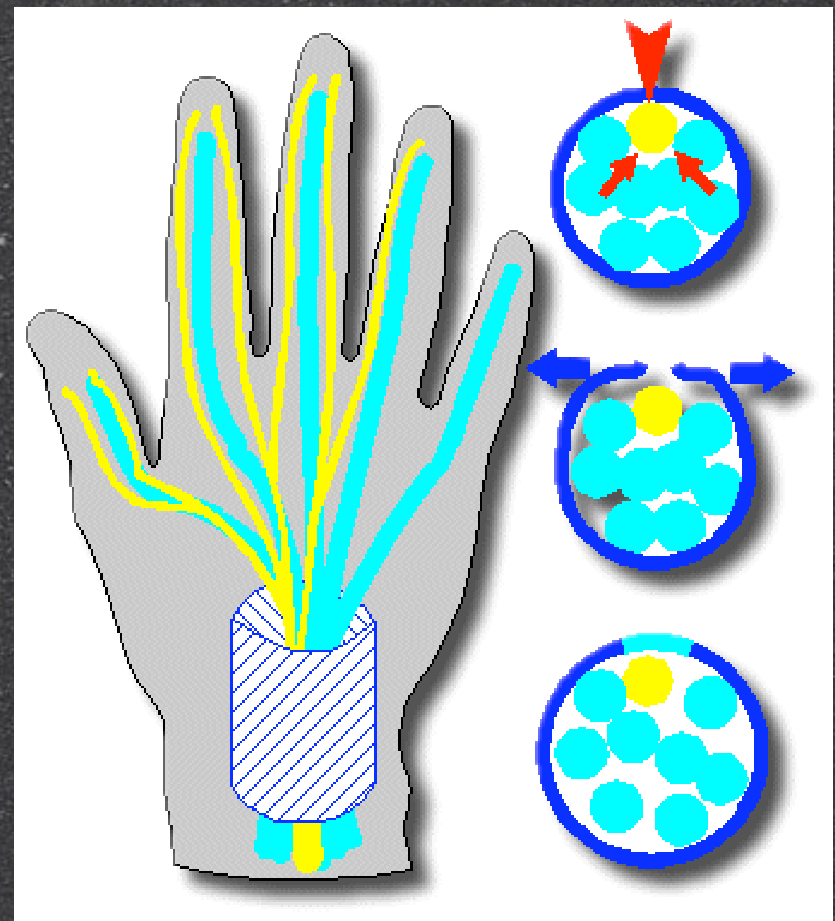

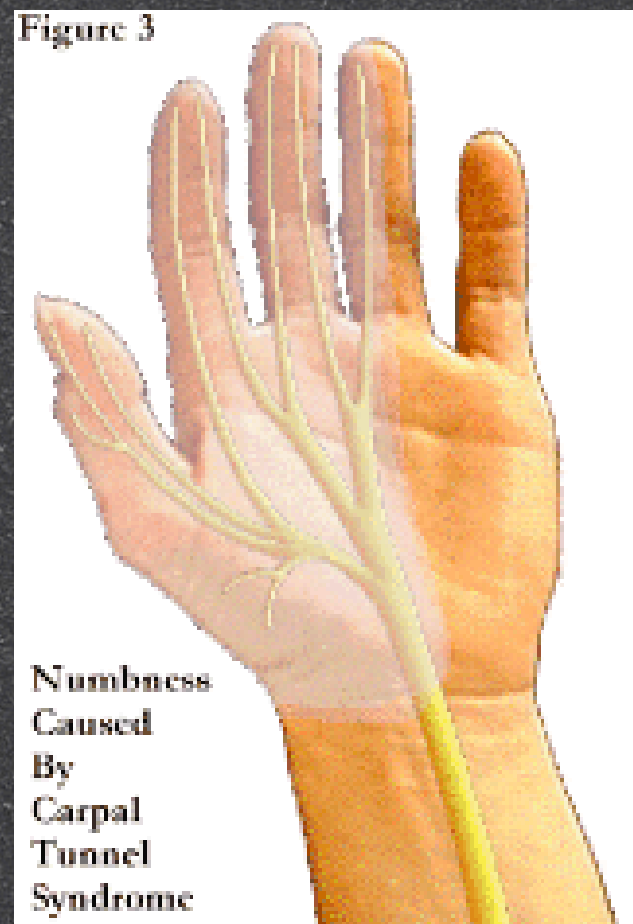
Figure 3



Laboratory and Review Exercises

Web sites

Numbers 1, 3, and 8